

Imbalance between Left and Right Dorsolateral Prefrontal Cortex in Major Depression Is Linked to Negative Emotional Judgment: An fMRI Study in Severe Major Depressive Disorder

Simone Grimm, Johannes Beck, Daniel Schuepbach, Daniel Hell, Peter Boesiger, Felix BERPohl, Ludwig Niehaus, Heinz Boeker, and Georg Northoff

Background: Although recent neuroimaging and therapeutic transcranial magnetic cortex stimulation (TMS) studies suggest imbalance between left and right dorsolateral prefrontal cortex (DLPFC) in major depressive disorder (MDD) the fundamental neuropsychological characterization of left DLPFC hypoactivity and right DLPFC hyperactivity in MDD remains poorly understood.

Methods: We used event-related functional magnetic resonance imaging (fMRI) to investigate neural activity in left and right DLPFC related to unattended (unexpected) and attended (expected) judgment of emotions. Participating in the study were 20 medication-free patients with MDD and 30 healthy subjects.

Results: The MDD patients showed hypoactivity in the left DLPFC during both unattended and attended emotional judgment and hyperactivity in the right DLPFC during attended emotional judgment. In contrast to healthy subjects, left DLPFC activity during emotional judgment was not parametrically modulated by negative emotional valence and was inversely modulated by positive emotional valence in MDD patients. Hyperactivity in the right DLPFC correlated with depression severity.

Conclusions: Results demonstrate that left DLPFC hypoactivity is associated with negative emotional judgment rather than with emotional perception or attention while right DLPFC hyperactivity is linked to attentional modulation. Left–right DLPFC imbalance is characterized in neuropsychological regard, which bridges the gap from resting metabolism and therapeutic repetitive transcranial magnetic stimulation effects to functional neuroanatomy of altered emotional–cognitive interaction in MDD.

Key Words: Emotional judgment, event-related fMRI, left–right DLPFC imbalance, MDD

Prefrontal brain regions, in particular the right and left dorsolateral prefrontal cortex (DLPFC), have been a focus of imaging studies in major depressive disorder (MDD). Using positron emission tomography (PET), resting-state studies revealed reduced cerebral blood flow and metabolism in the left DLPFC and hypermetabolism in the right DLPFC in acute MDD (1,2). The difference between left and right DLPFC functional state is also reflected in the therapeutic effects of repetitive transcranial magnetic stimulation (rTMS). Patients with MDD benefit from high-frequency (fast, i.e., increasing cortical activity) rTMS over the left DLPFC and low-frequency (slow, i.e., suppressing cortical activity) TMS over the right DLPFC (3–6). Both PET and rTMS findings have led to the imbalance hypothesis of MDD, which postulates prefrontal asymmetry with relative hypoactivity in the left DLPFC and relative hyperactivity in the right DLPFC (7–9). Similarly, recent studies using functional magnetic resonance imaging (fMRI) during emotional stimulation have also reported altered neuronal activity in left and right DLPFC in MDD (10–14). The specific neuropsychological components of

emotion processing (judgment, perception, and attention) that are associated with left DLPFC hypoactivity and right DLPFC hyperactivity remain to be investigated in MDD.

fMRI studies in healthy subjects demonstrated association of neural activity in both left and right DLPFC with emotional judgment rather than with emotional perception (15–21). Recent neuroimaging studies associated the left DLPFC specifically with emotional judgment per se and the right DLPFC with anticipation or attention to emotional judgment (22,23). In line with the valence-lateralization theory, which postulates a dominance of the left prefrontal cortex in positive emotions and of the right prefrontal cortex in negative emotions (9,24,25), fMRI studies in healthy subjects demonstrated linear or parametric dependence of negative and positive emotional judgments on neural activity in left and right DLPFC (20).

These findings in healthy subjects have important implications for patients with MDD who show extremely negative emotional judgments, the so-called negative emotional bias, and increased attention to their own judgments. In this study, event-related fMRI was used to investigate different aspects of emotional stimulation (judgment and perception of emotional pictures in both an unattended/unexpected and attended/expected mode). This allowed for direct comparison of emotional judgment and emotional perception, for the elimination of the perceptual component of emotion processing in emotional judgment, and thus for the isolation of its cognitive component. Presentation of pictures in both an attended and unattended mode revealed the impact of (preceding) attention on neural activity during emotional judgment. Finally, subjects' ratings of emotional valence and intensity were obtained in a postscanning session and correlated with neural activity observed during emotional judgment in fMRI. This allowed for the direct investigation of

From the Department of Psychiatry (SG, JB, DS, DH, HB, GN), University of Zurich, and Institute of Biomedical Engineering (PB), ETH and University of Zurich (PB), Switzerland; Departments of Neurology II (LN) and Psychiatry (GN), University of Magdeburg, and Department of Psychiatry (FB), Charité, Humboldt University of Berlin, Germany.

Address reprint requests to Georg Northoff, M.D., Ph.D., Department of Psychiatry, University of Magdeburg, Leipziger Strasse 44, 39120 Magdeburg, Germany; E-mail: georg.northoff@medizin.uni-magdeburg.de. Received January 30, 2007; revised April 19, 2007; accepted May 16, 2007.

the parametric modulation of positive and negative emotional valence (and intensity) by neural activity in the DLPFC.

We hypothesized that left DLPFC hypoactivity in MDD, as postulated by the imbalance hypothesis, is associated with more negative emotional judgments. Patients with MDD are assumed to show hyperactivity in the right DLPFC specifically during attended (expected) emotional judgment compared with unattended (unexpected) emotional judgment. Finally, on the basis of the valence-lateralization theory, we hypothesized that neural activity in the left DLPFC abnormally modulates positive and negative emotional valence in MDD compared with healthy subjects.

Methods and Materials

With approval by the local ethics commission, 20 patients with an acute MDD episode (26) were recruited from the inpatient department of Psychiatry at the University of Zurich (Switzerland). Patients had been free of psychotropic medication for a minimum of 1 week at scanning. One patient had to be excluded from the sample because of structural abnormalities in the three-dimensional (3D) T1-weighted anatomic scan. We also investigated 30 healthy subjects. One subject had to be excluded due to structural abnormalities in the 3D T1-weighted anatomic scan. Table 1 summarizes the major clinical and demographic data. The groups did not differ with respect to age and years of education. All subjects were right-handed as assessed by the Edinburgh Inventory for Handedness (27).

Experimental Task

The fMRI paradigm has been described elsewhere in full detail (20). The subjects were asked to view photographs taken from the International Affective Picture System (28) with positive and negative valence, which were matched with respect to intensity and dominance, as well as with respect to human faces and human figures. The pictures from the International Affective Picture System were presented for 4 sec and had to be judged as to whether they were positive or negative in content ("emotional judgment" [EJ], indicated by P/N) or passively viewed and therefore merely perceived ("picture viewing" [PV], indicated by A/A). It is important to stress that emotional judgment involved a binominal choice (positive or negative valence) rather than a graded response. In the case of "picture viewing," subjects were instructed to press a button arbitrarily without making a judgment to control for movement effects. In 50% of the trials, the pictures were preceded by the baseline condition (presentation of a fixation cross) and therefore viewed and judged in an unexpected condition (unPV, unEJ). In contrast, the other 50% of

pictures were preceded by an expectancy period of 8–11.5 sec, indicating the type of task associated with the picture subsequently presented (exPV, exEJ). The expectancy period was indicated by presentation of a white fixation cross on a dark background and a letter in one of the corners of the picture. "J" indicated expectancy of a subsequent judgment task, and "E" was associated with expectancy of subsequent picture viewing (29,30). After each picture presentation (PV and EJ), a fixation cross was presented for 6 to 8 sec. This allowed the subjects to recover from emotional stimulation and, in addition, served as a baseline condition to distinguish between positive and negative blood oxygen level-dependent (BOLD) responses (31). The baseline duration was randomly varied accounting for variable stimulus onset asynchrony (6.0, 6.5, 7.0, 7.5, 8.0 sec). A total of 158 trials were presented in six runs with 79 trials for PV and EJ, respectively.

Ratings of pictures were conducted outside the scanner immediately after the fMRI session. A selection of 151 pictures including those that had been presented in the paradigm, and 60 new pictures were presented to the subjects. Each picture was followed by a task period that consisted of an emotional intensity rating, valence rating, and recognition test. All three responses were given using a visual analogue scale. Valence assessment ranged on a continuum from *very negative* (1) to *very positive* (9). Emotional intensity rating scores ranged on a continuum from *low* (1) to *high* (9). For recognition of emotional pictures, choices ranged on a continuum from *definitely not recognized* (1) to *definitely recognized* (9). Postscanning ratings were conducted with 28 healthy subjects and 13 patients with an acute depressive episode.

Data Acquisition

Measurements were performed on a Philips Intera 3-T whole-body magnetic resonance unit equipped with an eight-channel Philips SENSE head coil (Philips Medical Systems, Amsterdam, the Netherlands). Functional time series were acquired with a sensitivity encoded (32) single-shot echo-planar sequence. The following acquisition parameters were used in the fMRI protocol: echo time = 35 msec, field of view = 22 cm, acquisition matrix = 80×80 , interpolated to 128×128 , voxel size: $2.75 \times 2.75 \times 4 \text{ mm}^3$, SENSE acceleration factor $R = 2.0$. Using a midsagittal scout image, 32 contiguous axial slices were placed along the anterior–posterior commissure (AC-PC) plane covering the entire brain with a repetition time of 3000 msec ($\theta = 82^\circ$).

Statistical Analysis

Reaction times and judgments (positive/negative rating) were analyzed in a multivariate analysis of variance (ANOVA) with the

Table 1. Clinical Characteristics of Depressed and Healthy Subjects

	Healthy Control (n = 29) M (SD)	MDD Patients (n = 19) M (SD)	t/ χ^2	p
Age	35.32 (7.26)	40.00 (9.89)	−1.84	.07
Gender, Male/Female, n (%)	8/21 (27.6/42.4)	8/11 (42.1/57.9)	1.08	.35
Education (years)	13.93 (2.82)	13.72 (4.70)	.17	.86
Age at Illness Onset	—	35.4 (11.1)	—	—
Duration of Illness (years)	—	6.6 (8.1)	—	—
Number of Episodes	—	1.8 (2.2)	—	—
Duration of Current Episode (weeks)	—	15.83 (16.24)	—	—
Beck Depression Inventory (range)	3.86 (3.09) (0–10)	29.94 (4.93) (24–37)	−19.17	.00 ^b
Hamilton Depression Rating Scale (range)	3.69 (1.56) (0–6)	33.12 (7.13) (24–52)	−16.78	.00 ^b
Duration of Washout Period (days) ^a	—	9.12 (7.98)	—	—

^aThree patients were antidepressant-naïve.

^bp < .01 (two sided).

factors group (healthy subjects/MDD patients), valence (positive/negative pictures), task (EJ/PV), and expectancy (with/without expectancy period). Postscanning ratings of valence, intensity, and recognition were analyzed in a group \times valence ANOVA.

fMRI data were analyzed using MATLAB 6.5.1 (Mathworks, Natick, Massachusetts) and SPM2 (Statistical Parametric Mapping Software; Wellcome Department of Imaging Neuroscience, London, United Kingdom; <http://www.fil.ion.ucl.ac.uk>) (33,34). For each subject, a design matrix was defined modeling unexpected and expected emotional judgment (unEJ, exEJ), unexpected and expected picture viewing (unPV, exPV), the expectancy periods preceding judgment (ExEJ) and picture viewing (ExPV) as separate events. In addition to these six events, the baseline condition was included in the design matrix and modeled separately, independent of the other events. We modeled the variable duration (6.0, 6.5, 7.0, 7.5, 8.0 sec) of the baseline, making explicit use of variable intervals in the data analysis (35,36). Additionally, for each experimental run, the six parameters obtained in the realignment procedure were included as regressors in the design matrix.

For the fMRI data group analyses, the contrast images from the analysis of the individual subjects were analyzed using two-sample *t* tests to compare signal changes in the previously mentioned conditions between healthy and MDD subjects. Activations are reported at a level of significance $p < .001$, uncorrected, and a cluster threshold of greater than 5. All group

comparisons included age as a covariate. To exclude possible influence of unequal sample size between healthy ($n = 29$) and MDD ($n = 19$) subjects, we also compared the 19 MDD subjects with an age-matched sample of 19 healthy control subjects. Results replicated those obtained from the full sample ($n = 29$).

For the region of interest (ROI) analyses of peak voxels, coordinates that were obtained in contrasts of the group analyses were selected. The ROIs were functionally defined by centering spheres on the respective peak voxels with a radius of 10 mm. Analyses were carried out for the right DLPFC (40, 24, 42) and left DLPFC (−42, 10, 30). Effect sizes (% signal change) for the various conditions were extracted for each subject separately and compared between groups using ANOVAs with follow-up *t* tests. For the extraction of effect sizes we used Marsbar (<http://www.sourceforge.net/projects/marsbar>). Signal changes are shown relative to the mean signal across the whole experiment. Time-course analyses were performed applying a finite impulse response model (FIR), which does not make an assumption on the resulting signal changes after stimulus presentation. Parameter estimates were calculated for 8 time bins of 1TR (= 3 sec) length for each regressor of the design matrix.

The scores from individual postscanning ratings of emotional valence, intensity, and recognition for positive and negative pictures were included as regressors in the design matrix for the healthy subjects and the MDD patient group separately (20). This yielded correlation maps for the relationship between *t* values

Table 2. Summary of Brain Regions Significantly Activated in Emotional Judgment

	Emotional Judgment		Emotional Judgment, Unexpected Mode		Emotional Judgement, Expected Mode		Emotional Judgement, Expected vs. Unexpected Mode	
	EJ > PV		unEJ > unPV		exEJ > exPV		exEJ > unEJ	
	H > MDD	MDD > H	H > MDD	MDD > H	H > MDD	MDD > H	H > MDD	MDD > H
Right DLPFC (BA 9)		40, 24, 42 3.30				46, 16, 48 3.34		22, 12, 50 4.52
Left DLPFC (BA 9)	−42, 10, 30 4.56		−40, 6, 30 4.12		−40, 10, 34 4.18			
Right Insula (BA 13)		48, 28, 0 3.77	40, 12, 10 3.61					
PCC/MPC (BA 6)	−2, −12, 56 4.39		−2, −12, 54 4.79		2, −6, 58 3.52			
Right Amygdala								24, 10, −12 3.23
Left Amygdala								−26, 14, −12 4.14
Right Occipital Cortex (BA 19)	28, −78, 22 3.81		28, −68, 24 3.79					
Left Occipital Cortex (BA 19)	−26, −78, 30 3.74		−26, −74, 28 3.59					
Medial Occipital Cortex (BA 7)		0, −72, 38 3.20				6, −68, 36 4.06		
Left Premotor Cortex (BA 4)	−38, −30, 50 3.88		−38, −22, 54 4.50					
Right Parietal Cortex (BA 40)		56, −56, 30 4.49				56, −54, 32 4.21		
Right Precentral Gyrus (BA 6)								48, −4, 44 3.40

BA, Brodmann's area; DLPFC, dorsolateral prefrontal cortex; EJ, emotional judgment; exEJ, expected emotional judgment; exPV, expected picture viewing; H, healthy control subjects; MDD, patients with major depressive disorder; MPC, medial parietal cortex; PCC, posterior cingulate cortex; PV, picture viewing; unEJ, unexpected emotional judgment; unPV, unexpected picture viewing.

The global height threshold for between-group comparisons (healthy vs. MDD subjects) was set to $p < .001$ uncorrected, the extent threshold to $k = 5$ voxels for all contrasts. The values in the table represent maximum *z* values with peak voxel coordinates in the Montréal Neurological Institute stereotactic space.

and subjects' rating scores. The threshold was set to $p < .005$, uncorrected, $k > 10$. Based on the results in healthy and MDD subjects an a priori ROI approach focusing on the left DLPFC was pursued. A left DLPFC ROI was functionally defined by the peak voxel of activation during $\text{unEJ} > \text{unPV}$ ($-40, 6, 40$). The effect sizes were extracted using Marsbar and then correlated with the individual rating scores. All correlation analyses were calculated separately for healthy and MDD subjects. Finally, using regres-

sion maps as described earlier, signal changes during $\text{EJ} > \text{PV}$ were correlated with BDI scores in MDD subjects, which yielded correlation maps for the relationship between signal intensity and depression severity. The threshold for significant correlation was set to $p < .005$, uncorrected, $k > 10$. A ROI in the right DLPFC was functionally defined by the peak voxel of activation during $\text{EJ} > \text{PV}$ ($36, 8, 38$). The effect sizes were extracted using Marsbar and then correlated with the individual Beck Depression

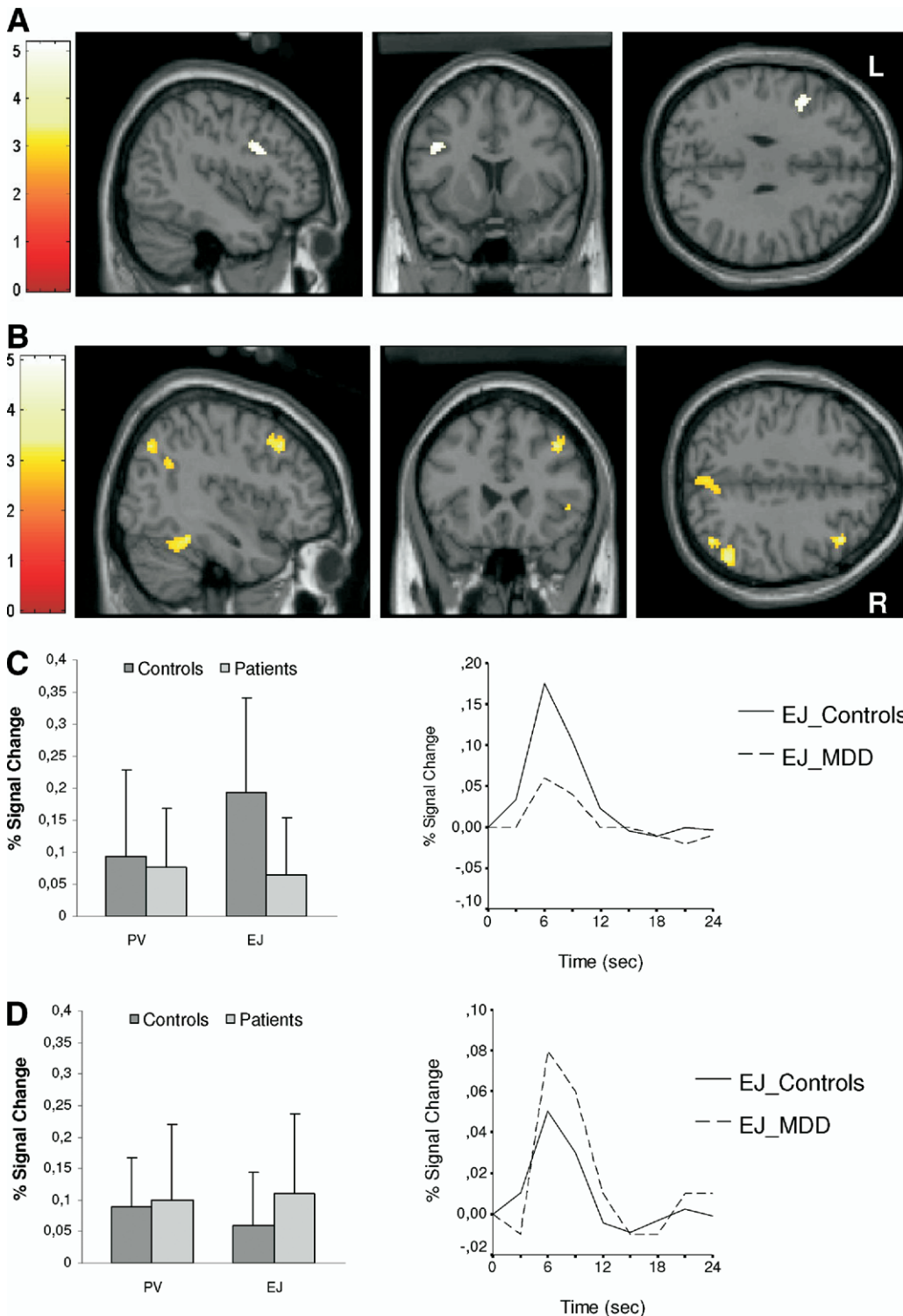


Figure 1. Comparisons between healthy subjects and depressed patients concerning emotional judgment and picture viewing ($\text{EJ} > \text{PV}$). Images show statistical parametric (T) maps for comparisons between healthy subjects and patients with major depressive disorder (MDD), overlaid on a single subject's normalized brain in the Montréal Neurological Institute stereotactic space ($p < .001$; uncorrected; $k > 5$). Bar diagrams and time courses show % signal changes in PV and EJ in healthy control subjects and MDD patients. **(A)** Signal changes during $\text{EJ} > \text{PV}$ in the left dorsolateral prefrontal cortex (DLPFC; $-42, 10, 30$; $z = 4.56$) in healthy control subjects. **(B)** Signal changes during $\text{EJ} > \text{PV}$ in the right DLPFC ($40, 24, 42$; $z = 3.30$) in MDD patients. **(C)** Left panel: bar diagrams represent the effect sizes (% signal change representing means and SD) in the left DLPFC for healthy control subjects and MDD patients in both PV and EJ. Right panel: corresponding time courses. **(D)** Left panel: Bar diagrams represent the effect sizes (% signal change representing means and SD) in the right DLPFC for healthy control subjects and MDD patients in both PV and EJ. Right panel: corresponding time courses.

Inventory (BDI) scores. For correlation analyses, we used Pearson correlation analysis and Spearman correlation analysis, respectively, if the underlying assumptions for a parametric statistic were violated.

Results

Behavioral Data

Reaction Times. Reaction times were longer in emotional judgment compared with picture viewing ($F = 13.99$, $df = 1$, $p = .0001$). In addition, MDD patients showed significantly longer reaction times ($F = 157.58$, $df = 1$, $p = .0001$). This effect concerned both picture viewing (healthy: $1.58 \pm .60$; MDD: $1.80 \pm .78$ [mean \pm SD]; $t = -7.94$, $df = 1886.37$, $p = .0001$) and emotional judgment (healthy: $1.63 \pm .63$; MDD: $1.89 \pm .81$ [mean \pm SD]; $t = -8.75$, $df = 1844.5537$, $p = .0001$). The results are indicative of a consistent psychomotor impairment in patients with MDD compared with healthy subjects.

Judgments. During the fMRI experiment, MDD patients judged the pictures significantly more negative than healthy subjects ($F = 74.66$, $df = 1$, $p = .000$). This difference particularly concerned the positive pictures (healthy: 7.24 ± 2.17 ; MDD: 6.90 ± 2.54 [mean \pm SD]; $F = 32.90$, $df = 1$, $p = .000$).

Postscanning Ratings

ANOVA. There was a significant effect of both participant group (Healthy, MDD) and picture valence (positive, negative) on ratings of intensity (healthy: 7.64 ± 1.84 ; MDD: 7.15 ± 2.38 [mean \pm SD]; $F = 82.13$, $df = 1$, $p = .000$), recognition (healthy: 5.52 ± 3.67 ; MDD: 5.14 ± 3.83 [mean \pm SD]; $F = 14.61$, $df = 1$, $p = .000$) and valence (healthy: 4.84 ± 3.44 ; MDD: 4.62 ± 3.56

[mean \pm SD]; $F = 20.32$, $df = 1$, $p = .000$). The MDD patients rated positive (healthy: 7.65 ± 1.81 ; MDD: 7.19 ± 2.29 [mean \pm SD]; $t = 5.68$, $df = 1770.13$, $p = .000$) and negative pictures (healthy: 7.64 ± 1.87 ; MDD: 7.12 ± 2.46 [mean \pm SD]; $t = 6.14$, $df = 1755.27$, $p = .000$) as less intense and recognized significantly fewer negative pictures (healthy: 5.45 ± 3.71 ; MDD: 4.91 ± 3.82 [mean \pm SD]; $t = 3.84$, $df = 2136.49$, $p = .000$) than healthy subjects. We found no differences between groups for recognition of positive pictures. There was no interaction effect between the factors group and picture valence.

fMRI Results

Effect of Emotional Judgment. To elucidate the effects of emotional judgment, we compared EJ > PV between MDD and healthy subjects. The MDD patients showed significantly lower signal intensities in the left DLPFC, as well as in the posterior cingulate cortex close to the medial parietal cortex (abbreviated as PCC/MPC henceforth), the left lateral premotor cortex, and the bilateral occipital cortex (see Table 2 and Figure 1A and 1C). Higher signal intensities in MDD patients were found in the right DLPFC, the right lateral parietal cortex, the right anterior insula, and the medial occipital cortex (see Table 2 and Figure 1B and 1D). Bar diagrams and time courses show clear differential involvement of right and left DLPFC in EJ and PV.

Emotional Judgment in an Unattended and Attended Mode. Emotional judgment was compared with emotional perception in both an unattended (unexpected), and attended (expected) mode between groups. The comparison UnEJ > UnPV yielded significantly lower signal intensities in the left DLPFC, as well as in the PCC/MPC, the right insula, the bilateral

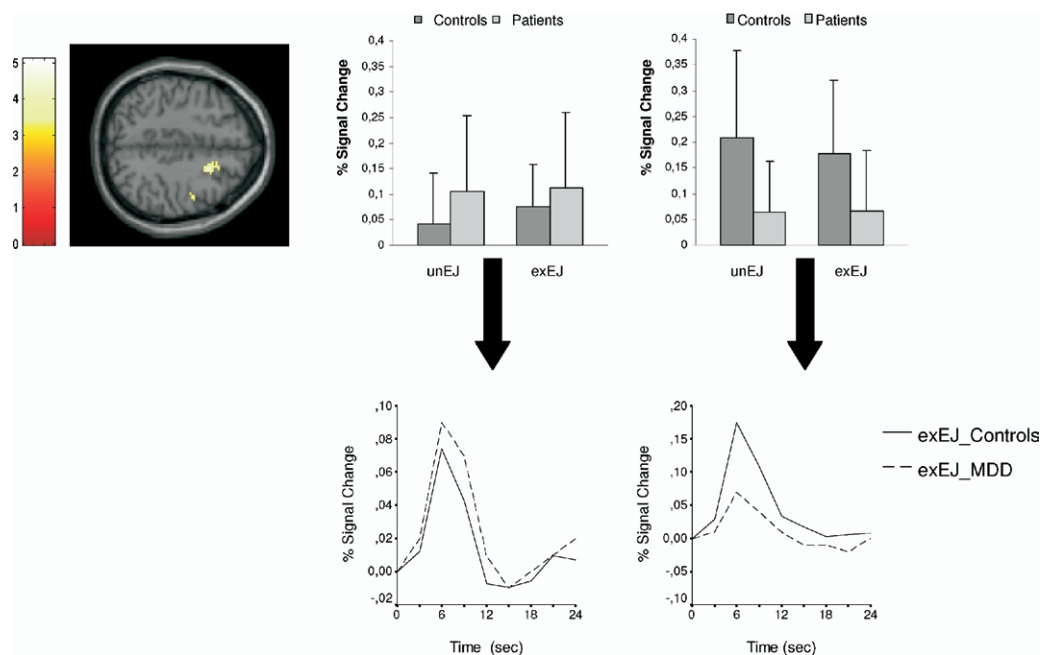


Figure 2. Comparisons between healthy subjects and depressed patients concerning expected emotional judgment and unexpected emotional judgment (exEJ > unEJ). Images show statistical parametric (T) maps for comparisons between healthy subjects and patients with major depressive disorder (MDD), overlaid on a single subject's normalized brain in the Montréal Neurological Institute stereotactic space ($p < .001$; uncorrected; $k > 5$). Bar diagrams show % signal changes in expected emotional judgment and unexpected emotional judgment in healthy control subjects and MDD patients. Time courses show % signal changes in expected emotional judgment in healthy control subjects and MDD patients. Left panel: signal changes during exEJ > unEJ in the right dorsolateral prefrontal cortex (DLPFC; 46, 16, 48; $z = 3.34$) in MDD patients. Center panel: bar diagrams represent the effect sizes (% signal change representing means and SD) in the right DLPFC region of interest (40, 24, 42) for healthy control subjects and MDD in both exEJ and unEJ. Right panel: bar diagrams represent the effect sizes (% signal change representing means and SD) in the left DLPFC region of interest (-42, 10, 30) for healthy control subjects and MDD in both exEJ and unEJ. Time courses (blood oxygen level-dependent curves) are demonstrated for expected EJ in right and left DLPFC regions of interest.

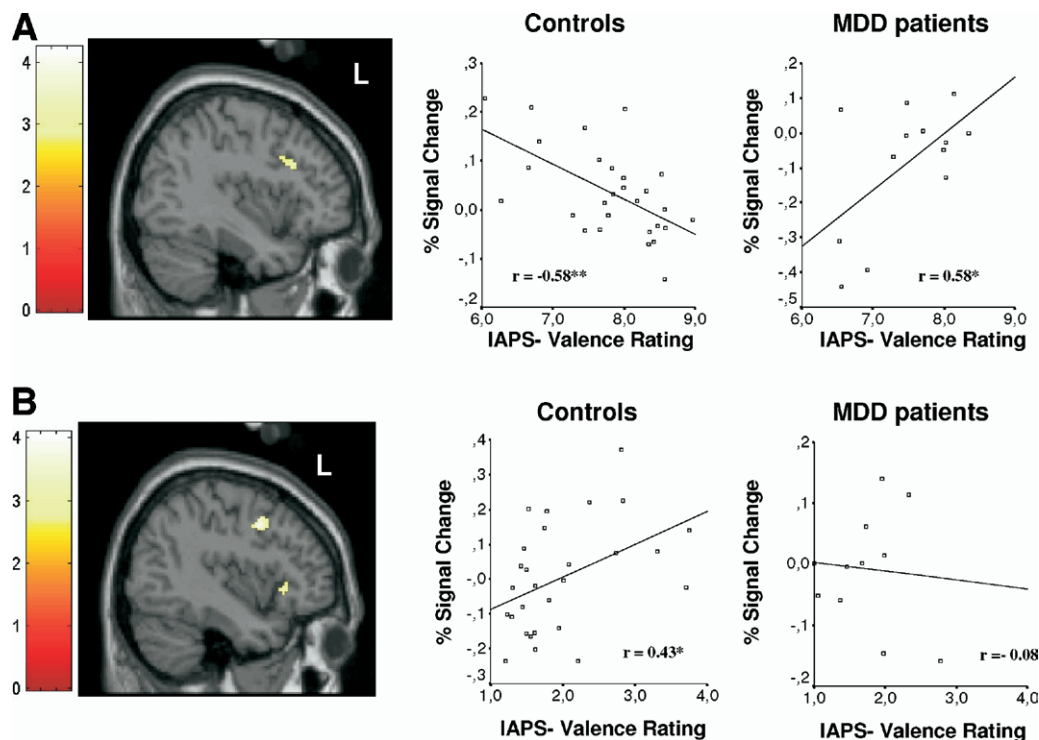


Figure 3. Correlation of postscanning subjective ratings for emotional valences with blood oxygen level–dependent (BOLD) signals obtained in the contrast unexpected emotional judgment (unEJ) > unexpected picture viewing (unPV) in healthy subjects and patients with major depressive disorder (MDD). Statistical parametric mapping images show regions of correlation between subjects' postscanning valence ratings for positive and negative pictures and single-subject contrasts of parameter estimates (% signal change) for the contrast unEJ > unPV (random effects whole-brain linear regression analysis). Statistical parametric (T) maps are overlaid on a single subject's normalized brain ($p < .005$; uncorrected; $k > 10$). The sagittal views represent the left hemisphere. Scatter plots show subjective valence scores on x axis and % signal change on y axis. Scatterplots are presented for both healthy and depressed subjects. Note that lower rating scores represent more negative picture ratings and that less negative effect sizes represent weaker negative BOLD responses. **(A)** Left panel: significant correlation of subjective ratings of positive pictures with signal changes in the left dorsolateral prefrontal cortex (DLPFC) is shown with coordinates ($-38, 22, 28; z = 3.06$) for healthy control subjects. Center panel: correlation curves for the relationship of left DLPFC % signal changes and subjective ratings of positive pictures in healthy controls ($**p < .01$). Right panel: correlation curves for the relationship of left DLPFC % signal changes and subjective ratings of positive pictures in MDD patients ($*p < .05$). **(B)** Left panel: significant correlation of subjective ratings of negative pictures with signal changes in the left DLPFC is shown with coordinates ($-40, 6, 40; z = 3.37$) for healthy control subjects. Center panel: correlation curves for the relationship of left DLPFC % signal changes and subjective ratings of negative pictures in healthy controls ($*p < .05$). Right panel: correlation curves for the relationship of left DLPFC % signal changes and subjective ratings of negative pictures in MDD patients.

occipital cortex, and the left lateral premotor cortex in MDD when compared with healthy subjects. No significant differential activations were found for the MDD subjects. The comparison of ExEJ > ExPV revealed significantly lower signal intensities in the left DLPFC and the PCC/MPC and significantly higher signal intensities in the right DLPFC, the medial occipital cortex, and the right parietal cortex in MDD patients (see Table 2).

Effects of Preceding Attention on Emotional Judgment. To elucidate the effects of preceding attention (emotional expectancy) on emotional judgment, ExEJ > UnEJ was compared between groups. MDD patients showed significantly higher signal intensities in the right DLPFC, the bilateral amygdala, and the right precentral gyrus, whereas no expectancy effect on subsequent pictures was observed in the left DLPFC (see Table 2 and Figure 2). No significant differential activations of the expectancy periods in left or right DLPFC were found for healthy or MDD subjects.

Effects of Emotional Valence on Emotional Judgment. To investigate parametric dependence of neural activity on emotional valence, postscanning ratings of positive and negative pictures were correlated with fMRI signal changes during emotional judgment. To exclude possible confounding effects of attention (as apparent in the right DLPFC), the correlation of

postscanning ratings with emotional judgment was performed for the contrast UnEJ > UnPV. In healthy subjects, this analysis revealed a significant negative correlation with positive emotional valence in the left DLPFC ($r = -.58, p < .01$). MDD patients showed a reversed correlation pattern with a significant positive correlation in this region ($r = .58, p < .05$; Figure 3A). Because there were some outliers in the MDD group (mean average scores for valence ratings ranging between 4 and 6, therefore indicating a neutral picture rating), the same correlation was calculated without these subjects, which did not alter the results ($r = .57, p = .084$).

In contrast to MDD patients, healthy subjects showed a significant positive correlation of negative emotional valence with signal intensities in the left DLPFC ($r = .43, p < .05$; see Figure 3B). Because again there were two outliers in the MDD group, the same correlation was calculated without these subjects, which did not alter the results ($r = -.31, p = .28$). In neither positive nor negative emotional valence was there any significant correlation with right DLPFC signal intensities in healthy or MDD subjects.

Correlation with Symptom Severity. To demonstrate the psychopathological relevance of altered neural activity in MDD, contrast estimates of EJ > PV were correlated with patients BDI

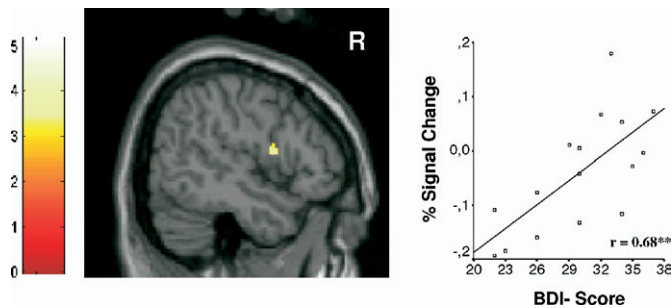


Figure 4. Correlation of depression symptom severity (Beck Depression Inventory [BDI]) with blood oxygen level–dependent (BOLD) signals obtained in the contrast emotional judgment (EJ) > picture viewing (PV) in patients with major depressive disorder (MDD). Statistical parametric mapping images show regions of correlation between depression severity ratings (BDI) and single-subject contrasts of parameter estimates (% signal change) for the contrast EJ > PV (random effects whole-brain linear regression analysis). Statistical parametric (T) maps are overlaid on a single subject's normalized brain ($p < .005$; uncorrected; $k > 10$). The sagittal view represents the right hemisphere. Scatter plots show depression severity ratings (BDI) on the x axis and % signal change on the y axis. Scatterplots are presented for depressed subjects. Left panel: significant correlation of depression severity ratings (BDI) with signal changes in the right dorsolateral prefrontal cortex (DLPFC) is shown with coordinates (36, 8, 38; $z = 3.29$) for MDD patients. Right panel: correlation curves for the relationship of right DLPFC % signal changes and depression severity ratings (BDI) in MDD patients (** $p < .01$).

scores. The MDD patients' subjective ratings of depression correlated significantly ($r = .68$, $p < .01$; see Figure 4) with signal changes in the right DLPFC.

Discussion

Studies using various imaging techniques (PET, fMRI, TMS) have demonstrated hypoactivity in the left DLPFC and hyperactivity in the right DLPFC in MDD (1–4,10–13). The neuropsychologic and psychopathologic significance of left and right DLPFC dysfunction remained unclear, however. Our study demonstrates the neuropsychologic correlates of left and right DLPFC dysfunction in MDD. The reduced activity in the left DLPFC is associated with emotional judgment rather than with emotional perception or (preceding) emotional attention, whereas increased activity in right DLPFC is related to attention to emotional judgment. While left DLPFC activity during emotional judgment was not parametrically modulated by negative emotional valence, it was inversely modulated by positive emotional valence in MDD patients. Hyperactivity in the right DLPFC correlated with depression severity.

Our findings in MDD are in line with studies in healthy subjects in which the left DLPFC has been associated with emotional judgment rather than with emotional perception (15–21). Our data suggest an altered relationship between left DLPFC and emotional judgment in MDD due to an abnormal modulation of left DLPFC neural activity by the evaluation of emotions. The disturbed modulation of neural activity in this region could also explain the therapeutic efficacy of left DLPFC rTMS in MDD, which, by stimulating and increasing neuronal excitability, might restore “normal” responsiveness of this region to emotional judgment.

Our results also specify the relationship between left DLPFC hypoactivity and emotional judgment with regard to emotional valence. Healthy subjects showed a negative correlation between left DLPFC neural activity and positive emotional valence, whereas MDD patients showed an inverse modulation with a positive correlation: the less signal intensity in the left DLPFC, the less positively MDD subjects rated positive emotional pictures. This is in accordance not only with left DLPFC hypoactivity as

observed here but also with the MDD patients' inability to look on something favorably even if it is genuinely positive. Most important, MDD patients did not show any parametric modulation of left DLPFC neural activity by negative emotional valence. Thus MDD patients seem to be unable to modulate DLPFC neural activity according to the degree of their negative emotions. Because only 13 patients undertook postscanning ratings, the previously described correlation data should be considered preliminary, however. Healthy subjects showed weaker BOLD signals in the left DLPFC when they had made more extreme emotional stimulus ratings in both the positive and negative picture condition, and thus one must also consider the possibility that emotional load, independent of valence, exerts an inhibitory effect on right DLPFC activity.

In contrast to the left DLPFC, we observed hyperactivity in the right DLPFC during emotional judgment. This is in accordance with previous studies in MDD showing similar results with either resting state hyperactivity or less signal decrease during emotional stimulation (14,37,38). Our study extends these findings by associating specifically right DLPFC hyperfunction with attentional modulation of emotional judgment. We observed hyperactivity in the right DLPFC only during attended (expected) emotional judgment but not during unattended (unexpected) emotional judgment. This was further confirmed by direct comparison between attended and unattended emotional judgment in which MDD patients again showed significantly higher signal intensities in the right DLPFC. Involvement of the right DLPFC in attention to emotion is well in line with previous imaging studies in healthy subjects, which showed involvement of this region in the anticipation of negative emotion (22,23,39).

The concurrent left DLPFC hypoactivity and right DLPFC hyperactivity during distinct dimensions of emotion processing lend strong support to the imbalance hypothesis of MDD. Until now this hypothesis was based predominantly on resting state metabolism and therapeutic rTMS effects. Resting state studies in the acute depressed state showed decreased metabolism in the left DLPFC and increased metabolism in the right DLPFC (40,41); TMS studies also suggest differential involvement of left and right DLPFC in MDD. High-frequency (stimulating) TMS is therapeutically beneficial over the left DLPFC, whereas in the right DLPFC, low-frequency (suppressing) TMS shows therapeutic effects (5,6). However, neuropsychological characterization and functional neuroanatomy of left and right DLPFC remained unclear. This study demonstrates that left DLPFC hypoactivity is related to emotional judgment with abnormal modulation by positive and negative emotional valence. Right DLPFC hyperactivity seems to be associated with attentional modulation of emotional judgment. This characterization of left and right DLPFC is in accordance with the opposite effects of therapeutic rTMS in which stimulating TMS activates the hypoactive left DLPFC, whereas suppressing TMS decreases neural activity in the hyperactive right DLPFC. Future studies should include remitted MDD patients to distinguish between state and trait variables in alterations of left and right DLPFC neural activity.

In conclusion, our results in MDD patients show opposite abnormal changes in neural activity and a differential neuropsychological characterization of left and right DLPFC. Our results provide strong support for the left–right DLPFC imbalance hypothesis in MDD and substantiate it further in a pathophysiological and neuropsychological regard. The findings of this study contribute to the understanding of the pathophysiological and neuropsychological mechanisms of cognitive symptoms in MDD

and their possible therapeutic manipulation by cognitive behavioral therapy (CBT), deep brain stimulation, or TMS (42).

The authors thank Conny Schmidt and Michael Wyss of the Institute of Biomedical Engineering, ETH, and University of Zurich for their contributions to this study. The study was supported by a Heisenberg grant from the German Research Foundation (Grant No. DFG 304/4-1 to G.N.); the Salus Foundation (to G.N.); the Swiss National Research Foundation (Grant No. 3100A0-100830) to G.N. and H.B.; a grant of the Research Foundation at the University of Zurich, Organon Switzerland, to G.N. and H.B.; a grant of the Salus Foundation Sachsen Anhalt/Germany to G.N.; a grant from ETH Zurich (SEP) and Philips Medical Systems, Best, NL, to P.B.; the Hartmann-Müller-Foundation to H.B. and G.N.; and the Gebert-Rüf-Foundation to H.B. and G.N.

The authors do not have any financial disclosures.

1. Phillips ML, Drevets WC, Rauch SL, Lane R (2003): Neurobiology of emotion perception II: Implications for major psychiatric disorders. *Biol Psychiatry* 54:515–528.
2. Mayberg HS (2003): Modulating dysfunctional limbic–cortical circuits in depression: Towards development of brain-based algorithms for diagnosis and optimised treatment. *Br Med Bull* 65:193–207.
3. Burt T, Lisanby SH, Sackeim HA (2002): Neuropsychiatric applications of transcranial magnetic stimulation: A meta analysis. *Int J Neuropsychopharmacol* 5:73–103.
4. Gershon AA, Dannon PN, Grunhaus L (2003): Transcranial magnetic stimulation in the treatment of depression. *Am J Psychiatry* 160:835–845.
5. Fitzgerald PB, Brown TL, Marston NAU, Daskalakis ZJ, de Castella A, Kulkarni J (2003): Transcranial magnetic stimulation in the treatment of depression: A double-blind, placebo-controlled trial. *Arch Gen Psychiatry* 60:1002–1008.
6. Bormpohl F, Fregni F, Boggio PS, Thut G, Northoff G, Otachi PTM, *et al.* (2006): Effect of low-frequency transcranial magnetic stimulation on an affective go/no-go task in patients with major depression: Role of stimulation site and depression severity. *Psychiatry Res* 141:1–13.
7. Sackeim HA, Greenberg MS, Weiman AL, Gur RC, Hungerbühler JP, Geschwind N (1982): Hemispheric asymmetry in the expression of positive and negative emotions. Neurologic evidence. *Arch Neurol* 39:218.
8. Maeda F, Keenan JP, Pascual-Leone A (2000): Interhemispheric asymmetry of motor cortical excitability in major depression as measured by transcranial magnetic stimulation. *Br J Psychiatry* 177:169–173.
9. Davidson RJ, Irwin W (1999): The functional neuroanatomy of emotion and affective style. *Trends Cogn Sci* 3:11–21.
10. Keedwell PA, Andrew C, Williams SCR, Brammer MJ, Phillips ML (2005): The neural correlates of anhedonia in major depressive disorder. *Biol Psychiatry* 58 843–853.
11. Fahim C, Stip E, Mancini-Marie A, Mensour B, Leroux JM, Beaudoin G, Bourgouin P, Beaugregard M (2004): Abnormal prefrontal and anterior cingulate activation in major depressive disorder during episodic memory encoding of sad stimuli. *Brain Cogn* 54:161–163.
12. Lawrence NS, Williams AM, Surguladze S, Giampietro V, Brammer MJ, Andrew C, *et al.* (2004): Subcortical and ventral prefrontal cortical neural responses to facial expressions distinguish patients with bipolar disorder and major depression. *Biol Psychiatry* 55:578–587.
13. Davidson RJ, Irwin W, Anderle MJ, Kalin NH (2003): The neural substrates of affective processing in depressed patients treated with venlafaxine. *Am J Psychiatry* 160:64–75.
14. Liotti M, Mayberg HS, McGinnis S, Brannan SL, Jerabek P (2002): Unmasking disease-specific cerebral blood flow abnormalities: Mood challenge in patients with remitted unipolar depression. *Am J Psychiatry* 159:1830–1840.
15. Lange K, Williams LM, Young AW, Bullmore ET, Brammer MJ, Williams SCR, *et al.* (2003): Task instructions modulate neural responses to fearful facial expressions. *Biol Psychiatry* 53:226–232.
16. Nakamura K, Kawashima R, Ito K, Sugiura M, Kato T, Nakamura A, *et al.* (1999): Activation of the right inferior frontal cortex during assessment of facial emotion. *J Neurophysiol* 82:1610–1614.
17. Ochsner KN, Bunge SA, Gross JJ, Gabrieli JD (2002): Rethinking feelings: An fMRI study of the cognitive regulation of emotion. *J Cogn Neurosci* 14:1215–1229.
18. Keightley ML, Winocur G, Graham SJ, Mayberg HS, Hevenor SJ, Grady CL (2003): An fMRI study investigating cognitive modulation of brain regions associated with emotional processing of visual stimuli. *Neuropsychologia* 41:585–596.
19. Northoff G, Heinzel A, Bormpohl F, Niese R, Pfennig A, Pascual-Leone A, Schlaug G (2004): Reciprocal modulation and attenuation in the prefrontal cortex: An fMRI study on emotional–cognitive interaction. *Hum Brain Mapp* 21:202–212.
20. Grimm S, Schmidt CF, Bormpohl F, Heinzel A, Dahlem Y, Wyss M, *et al.* (2006): Segregated neural representation of distinct emotion dimensions in the prefrontal cortex—an fMRI study. *NeuroImage* 30:325–340.
21. Taylor SF, Phan KL, Decker LR, Liberzon I (2003): Subjective rating of emotionally salient stimuli modulates neural activity. *NeuroImage* 18:650–659.
22. Ueda K, Okamoto Y, Okada G, Yamashita H, Hori T, Yamawaki S (2003): Brain activity during expectancy of emotional stimuli: An fMRI study. *Neuroreport* 14:51–55.
23. Nitschke JB, Mackiewicz KL (2005): Prefrontal and anterior cingulate contributions to volition in depression. *Int Rev Neurobiol* 67:73–94.
24. Murphy FC, Nimmo-Smith I, Lawrence AD (2003): Functional neuroanatomy of emotions: A meta-analysis. *Cogn Affect Behav Neurosci* 3:207–233.
25. Wager TD, Phan KL, Liberzon I, Taylor SF (2003): Valence, gender, and lateralization of functional brain anatomy in emotion: A meta-analysis of findings from neuroimaging. *NeuroImage* 19:513–531.
26. American Psychiatric Association (1994): *Diagnostic and Statistical Manual of Mental Disorders*. Washington, DC: American Psychiatric Publishing.
27. Oldfield RC (1971): The assessment and analysis of handedness: The Edinburgh inventory. *Neuropsychologia* 9:97–113.
28. Lang PJ, Bradley MM, Cuthbert BN (1999): International Affective Picture System (IAPS). Gainesville: Center for Research in Psychophysiology, University of Florida.
29. Kastner S, Pinsk MA, De Weerd P, Desimone R, Ungerleider LG (1999): Increased activity in human visual cortex during directed attention in the absence of visual stimulation. *Neuron* 22:751–761.
30. Driver J, Frith C (2000): Shifting baselines in attention research. *Nat Rev Neurosci* 1:147–148.
31. Stark CE, Squire LR (2001): When zero is not zero: The problem of ambiguous baseline conditions in fMRI. *Proc Natl Acad Sci U S A* 98:12760–12766.
32. Pruessmann KP, Weiger M, Scheidegger MB, Boesiger P (1999): SENSE: Sensitivity encoding for fast MRI. *Magn Reson Med* 42:952–962.
33. Friston KJ, Frith CD, Turner R, Frackowiak RSJ (1995): Characterizing evoked hemodynamics with fMRI. *NeuroImage* 2:157–165.
34. Friston KJ, Holmes AP, Poline JB, Grasby PJ, Williams SCR, Frackowiak RSJ, *et al.* (1995): Analysis of fMRI time-series revisited. *NeuroImage* 2:45–53.
35. Burock MA, Buckner RL, Woldorff MG, Rosen BR, Dale AM (1998): Randomized event-related experimental designs allow for extremely rapid presentation rates using functional MRI. *Neuroreport* 9:3735–3739.
36. Sakai K, Passingham RE (2003): Prefrontal interactions reflect future task operations. *Nat Neurosci* 6:75–81.
37. Ebert D, Feistel H, Barocka A (1991): Effects of sleep deprivation on the limbic system and the frontal lobes in affective disorders: A study with Tc-99m-HMPAO SPECT. *Psychiatry Res* 40:247–251.
38. Kocmur M, Milcinski M, Budihna NV (1998): Evaluation of brain perfusion with technetium-99m bicisate single-photon emission tomography in patients with depressive disorder before and after drug treatment. *Eur J Nucl Med* 25:1412–1414.
39. Bormpohl F, Pascual-Leone A, Amedi A, Merabet LB, Fregni F, Gaab N, *et al.* (2006): Attentional modulation of emotional stimulus processing: An fMRI study using emotional expectancy. *Hum Brain Mapp* 27:662–677.
40. Sackeim HA, Prohovnik I, Moeller JR, Mayeux R, Stern Y, Devanand DP (1993): Regional cerebral blood flow in mood disorders: II. Comparison of major depression and Alzheimer's disease. *J Nucl Med* 34:1090–1101.
41. Mottaghy FM, Keller CE, Gangitano M, Ly J, Thall M, Parker JA, *et al.* (2002): Correlation of cerebral blood flow and treatment effects of repetitive transcranial magnetic stimulation in depressed patients. *Psychiatry Res* 115:1–14.
42. Mayberg HS, Lozano AM, Voon V, McNeely HE, Seminowicz D, Hamani C, *et al.* (2005): Deep brain stimulation for treatment-resistant depression. *Neuron* 45:651–660.