Curr Psychiatry Rep (2013) 15:351
DOI 10.1007/s11920-013-0351-x

SEXUAL DISORDERS (JP FEDOROFF, SECTION EDITOR)

Neuroimaging in Pedophilia

Christine Wiebking · Georg Northoff

Abstract Paraphilia is a set of disorders characterized by abnormal sexual desires. Perhaps most discussed amongst them, pedophilia is a complex interaction of disturbances of the emotional, cognitive and sexual experience. Using new imaging techniques such as functional magnetic resonance imaging, neural correlates of emotional, sexual and cognitive abnormalities and interactions have been investigated. As described on the basis of current research, altered patterns of brain activity, especially in the frontal areas of the brain, are seen in pedophilia. Building on these results, the analysis of neural correlates of impaired psychological functions opens the opportunity to further explore sexual deviances, which may contribute ultimately to the development of tools for risk assessment, classification methods and new therapeutic approaches.

Keywords Paraphilia · Pedophilia · Neuroimaging · fMRI · Neurofeedback · Real-time fMRI · Sexual disorders · Psychiatry

Introduction

Paraphilia, according to DSM-IV-TR, involves sexual arousal and gratification towards sexual behaviour that is atypical and extreme [1]. It includes sexual attraction towards non-human objects and humans, including children. The latter is described as pedophilia and since it is in terms of research in brain imaging a well investigated topic, it will be the focus of the following article.

Pedophilia, often not distinguished from the broader phenomenon of child sexual abuse in public discourse [2, 3••], is a specifically sexual preference for children and does not necessarily include child sexual abuse [4]. One-half of sexual offenses against children are perpetrated by individuals with pedophilia [4–7], indicating a differentiation between pedophilia in the sense of a sexual disorder and the sexual abuse of children without an underlying sexual disorder.

Pedophilia, mostly documented in male patients, is commonly found among paraphilic disorders examined in forensic psychiatry, making this disorder a useful case study amongst this wider category. The diagnostic criteria of pedophilia, criticized repeatedly [8], are based on the following three conditions. Firstly, the length of time that symptoms have been present is a critical factor. The recurrence over a period of at least 6 months of intense sexual fantasies, sexual urges, or behaviours involving sexual activity towards prepubescent children (generally under 13 years of age) [9] are documented. Secondly, a significant psychological distress or personal difficulty for the patient exists. The presence of fantasies, sexual urges, or behaviours must be present that cause significant problems in daily life. Thirdly, the age difference between perpetrator and victim is noted. According to the American Psychiatric Association, the perpetrator must be at least 16 years old and at least 5 years older than the victim [9]. The treatment of a pedophilic disorder is considered to be very difficult [10].

The aetiology of sexual deviance is a complex construct, including dynamic and interacting elements of emotional abnormalities, cognitive distortions and social problems. One component of an aetiological model is the presence of a strong emotional attachment to children. This has the implication of influencing the ability to judge a child's

This article is part of the Topical Collection on *Sexual Disorders*

C. Wiebking
Mind, Brain Imaging and Neuroethics, Royal Ottawa Healthcare, Institute of Mental Health Research, Ottawa, Canada

G. Northoff (✉)
Mind, Brain Imaging and Neuroethics, Royal Ottawa Healthcare Group, University of Ottawa, Institute of Mental Health Research, 1145 Carling Avenue, Room 6435, Ottawa, ON K1Z 7K4, Canada
e-mail: georg.northoff@theroyal.ca

Published online: 24 February 2013

reactions in an appropriate manner [2]. In addition, the preponderance of male offenders [2, 11] and the manifestation of pedophilic tendencies already during adolescence [12, 13] are other factors that need to be investigated considering a biopsychosocial model of disease. However, although research carried out to date has provided fundamental insights into aspects of pedophilia, it has not yet led to a complete and uncontroversial construct of the condition.

Building upon such prior psychiatric research, the more recent development of neuroimaging techniques like functional magnetic resonance imaging (fMRI) or positron emission tomography (PET) has facilitated research targeting the underlying neurobiological and psychological mechanisms of paraphilic disorders such as pedophilia. This research into such basic mechanisms may allow the creation of a more concrete and accepted description of these conditions. The aim of this article is thus to describe some of this imaging-based research and to link it to paraphilic disorders, focussing on pedophilia as a case-in-point. The article begins with a brief introduction to fMRI, followed by a description of the neural mechanisms underlying sexual processing, and a description of a selected fMRI study in pedophilia. It concludes with a perspective outlining the potential for using imaging techniques to decrease psychological strains due to sexual deviances.

Neuroimaging Using fMRI

Neuroimaging techniques allow the investigation of different aspects of the brain *in vivo*. The most prominent and popular amongst these techniques is functional magnetic resonance imaging (fMRI). The underlying physiological principle of functional imaging of the brain is based on the close link between neural activity and energy metabolism, which was first described in 1890 by Roy and Sherrington. Due to neural activation, induced for example by a cognitive task, brain areas involved in the particular task show an increase in metabolic activity. This causes an increased consumption of oxygen and glucose in these brain areas, with these being supplied through the bloodstream, the former via red blood cell haemoglobin. The increasing energy demands for oxygen and glucose in brain areas involved in the task thus lead to local increases in blood flow (HR, haemodynamic response).

Functional magnetic resonance imaging works on the basis of the differing magnetic properties (susceptibility) of oxygen-rich (oxygenated) or oxygen-poor (not oxygenated, deoxygenated) haemoglobin. Hence, changes in the concentration of deoxygenated blood, peaking at about 2 seconds after demand-onset and then declining [14], provide a measure of brain function based on blood-oxygenation-level dependent (BOLD) contrast. Using fMRI, images of perfusion-related changes in the oxygen concentration are created that are correlated with neuronal activity, making them an indirect measure of neuronal activity [15].

Echo planar imaging (EPI), invented by Sir Peter Mansfield [16], is a specific MRI pulse sequence that enables fast data acquisition of the whole brain. EPI is the technique most frequently used to acquire the BOLD contrast [17]. This particularly fast measuring sequence enables whole brain recordings of usually around 30 layers in 1-3 seconds, and is thus ideal to fit with the temporal behaviour of the blood flow responses induced by neuronal activity. Although the temporal resolution of fMRI (in seconds) is lower compared to techniques such as electroencephalography (EEG, in milliseconds), the link between neuronal activity and BOLD contrast has been convincingly shown [18].

On the basis of the strength of the BOLD signal conclusions can be drawn regards neuronal activity during a certain task. Another significant advantage of the fMRI technique is its non-invasive character – participants need no contrast agents. Moreover, exposure to radiation is not necessary, as it is the case in studies using positron emission tomography (PET). Overall, no long term effects from MRI have been observed so far. Functional magnetic imaging offers in addition a very high spatial resolution of up to 1.5 mm, so that even the differentiation of cortical columns is possible [19].

Neuroimaging Focussing on Mechanisms Underlying Sexual and Emotional Processing in Neurotypical Individuals

Due to developments in neuroimaging techniques, our knowledge about the underlying neurobiological processes of sexual and emotional experience has grown in recent years. Basing on their fMRI results in healthy men, Redouté et al. [20] suggested four components to be central in a neurobehavioural model of sexual arousal: he distinguished cognitive, motivational, emotional, and autonomic responses from each other, though they are closely interrelated [20]. These components can be described as follows:

Firstly, the cognitive component refers to the categorization and evaluation of the stimuli and the particular focus of attention to sexual stimuli. On the neural level, these processes are related to regions of the orbitofrontal cortex and the superior parietal cortex [21].

Secondly, the emotional component concerns the hedonic quality of a stimulus, which describes the degree of pleasantness or unpleasantness of a stimulus as it may be associated with varying degrees of arousal. Here, the neural activity of the secondary somatosensory cortex and the insular cortex are considered central [22]. In addition, the amygdala plays a critical role in the evaluation of the emotional content of sexual stimuli as well as in the general processing of emotions [21, 23]. The dorsomedial prefrontal

cortex also seems to be involved in these processes, allowing a higher second-order representation of the respective emotional content (a so-called metarepresentation) and its relevance for the own self [24–27]. It should be noted, however, that neither of these regions is exclusively and specifically associated with the respective functions; all regions also mediate other functions and processes.

Thirdly, the motivational component is related to regions in the caudal part of the left anterior cingulate gyrus. Fourthly, the autonomic component includes effects on cardiovascular and respiratory levels and correlates with neuronal activations in the hypothalamus, insula and the rostral part of the anterior cingulate cortex [21, 22, 28].

In summary, these results show that the neurobiology underlying human sexual and emotional behaviour are multidimensional events. They consist of interrelated physiological and psychological processes. The latter issue has been the focus of interest in an fMRI study conducted by Hamann et al. [29]. They demonstrated that gender-specific processing of sexual pictures revealed stronger neural activity in the hypothalamus and amygdala in male subjects compared to female subjects. Since psychological components have an influence on the neural activity of different aspects of sexual-emotional processing, it is feasible to study the underlying neural correlates of a deviant sexual disorder like pedophilia. This may improve our understanding of the dysfunction in the sexual, emotional and cognitive domains of paraphilic disorders.

Neuroimaging in Pedophilia

Studying psychiatric disorders opens the opportunity to further explore the role of sexual processing by linking altered behaviour to neural activity. Thereby, conclusions can be drawn about particular brain structures involved in processes like sexual processing and how neural dysfunction of particular brain regions like the frontal cortex can be related to behavioural symptoms seen in psychiatric populations. Findings in such studies can provide novel insights into the neural underpinnings of paraphilic disorders and may lead to potential reclassifications of psychiatric disorders on a neurobiological basis. Brain regions abnormally involved in processes like sexual processing might serve due to their association with emotional processing also as target regions for treating affective disorders (see below comorbidity rates between pedophilia and affective disorders).

In view of the neural correlates of sexual-emotional processing in healthy individuals, deficits in these in persons with pedophilia can be interpreted as a modified interaction between emotional and cognitive functions. Indicative of this are comorbidity rates of persons with pedophilia with other major psychiatric disorders like affective disorders (60 %-80 %), anxiety disorders (50 %-60 %), and personality disorders (70 %-80 %) [30–32]. Abnormalities in emotional processes might be responsible for a lack of understanding inappropriate behaviour and the harm that their actions cause [32–35].

A closer look at these deficits on the emotional and cognitive levels might lead to identifying a different pattern of neural activation in persons with pedophilia. One region of particular interest in this context is the frontal cortex, since several studies have already shown aberrant activation patterns in pedophilic patients. The orbitofrontal cortex is associated with the cognitive component of sexual-cognitive processing (see above) and is frequently involved in cases of pedophilia [36, 37••, 38•]. Lesions in this area or abnormal activity can affect the disinhibition of sexual behaviour as well as have implications for emotional processes [39]. An fMRI case study of pedophilia from Dressing et al. [40] also demonstrated abnormal activation patterns in this area and in the amygdala, a brain structure associated with emotional evaluation. This region was also found to be abnormally activated in sadists compared to non-sadists when viewing pain pictures [38•]. In a lesion study using positron emission tomography (PET), both of the male pedophilic patients reported by Mendez et al. showed fronto-temporal dementia and bilateral hippocampal sclerosis [41]. A more recent study by Mendez and Shapira [39] underlined the hypothesis that neurological disorders affecting frontal brain areas were associated with pedophilia in male patients, while a case report by Burns and Swerdlow described a 40-year-old male patient with a tumor in the right orbitofrontal cortex [36]. These impairments in the regions in question suggest a role in the etiology of pedophilia and demonstrate the potential relevance of organic damage to some cases [37••, 39].

In line with the observation that persons with pedophilia and non-pedophilic individuals show a similar pattern of neural activation in frontal areas during visual stimulation with their preferred picture material [37••, 42••], a recent study conducted by Ponseti et al. [43••] showed first results using these neural patterns to successfully differentiate between male pedophilic and non-pedophilic participants [43••]. This was done by using an automatic classification procedure, a method used in statistics and machine learning to find a linear combination of features to separate different groups from each other - like in this case a classification of male pedophilic versus non-pedophilic participants [43••].

A study by Schiltz et al. [44] demonstrated anatomic-structural changes in male patients with pedophilia. They observed volume reductions in frontal brain areas and the amygdala in individuals with pedophilia. Especially, a significant reduction of right amygdalar volume in persons with pedophilia in comparison with healthy subjects was demonstrated. Walter et al. [45] investigated the same group in fMRI and showed neural abnormalities in the dorsolateral

prefrontal cortex during visual processing of sexual stimuli (see details below).

Another study by Cohen et al. [33] investigated 22 male, heterosexual, nonexclusive patients with pedophilia and compared them with neurotypical individuals. In addition, seven participants of each group underwent PET scanning. The authors reported on the behavioural level a lack of assertiveness, sociopathy, low self-esteem, and cognitive distortions. These deficits may have affected the motivation of pedophilic acts [35, 46] including an effect towards empathy deficits [47]. Interestingly, results of the PET data suggested on the neural level decreased glucose metabolism in frontal and temporal brain areas, which indicates impaired neural function in these particular regions. As noted above, abnormal neural activity specifically in frontal brain regions might lead to sexual hyperarousal and affect emotional processes [33, 39]. In line with these findings, Cantor et al. [48] reported reduced white matter in persons with pedophilia compared to non-pedophilic persons and hypothesized dysfunctional frontal network activity, which lead to abnormalities in the evaluation of external stimuli as sexual relevant [48]. A specific reanalysis of this data set [49] suggested a distinction between individuals with pedophilia and individuals with hebephilia (attracted to early pubertal children) on the basis of white matter differences, although more recent and precise imaging techniques like diffusion tensor imaging (DTI) remain to be investigated to confirm these results.

Taken together, deficits in structure and function of the brain have been associated with paraphilic disorders, specifically pedophilia in male individuals. Whilst neural deficits involved in emotional processing can be related to abnormal functioning of subcortical regions, such as the amygdala [38•, 44, 50••], neural deficits particularly involved in the processing of sexual stimuli can be related to deficits in frontal brain areas [37••, 42••, 45, 51], making these regions to targets for treatment approaches (see below) .

Neuroimaging in Pedophilia: A Specific fMRI Study

Walter et al. [45] conducted an fMRI study comparing 13 male patients with pedophilia to a control group of 13 neurotypical male adults. In order to make both groups closely comparable, the control group was carefully matched for intelligence, gender, age, and years of education. Patients had committed sexual offenses against children younger than 10 years of age. They completed the Multiphasic Sex Inventory [52] (MSI), an inventory that elicits and quantifies information about sexual abnormalities in a forensic sample.

Since in general the comparability and reproducibility of neuroimaging studies is of high importance, the fMRI paradigm was constructed using pictures that were taken from the International Affective Picture System [53]. This database of photographs, developed by Lang since the late 1980s [53, 54], is commonly used in research of emotional processes. In addition, it involves detailed characterizations of dimensions such as valence, arousal, and dominance [55], making it to an ideal instrument to conduct reproducible studies in research of emotions.

All participants were asked to passively view neutral, erotic, and non-erotic emotional IAPS pictures during the fMRI scan. In total, 256 pictures were presented in a randomized order. Each picture was shown for five seconds. To control for attentional effects, 128 pictures were proceeded by expectancy periods. These periods were indicated by different kinds of arrows (e.g. an arrow pointing to the right side signals an upcoming erotic picture). Since each period of passive picture viewing lead to increased neural activity, these periods were followed by rest conditions, which were indicated by the standardized fixation cross. This was done to ensure a normalization of brain activity after stimulation by a picture.

To examine neural differences between neurotypical and pedophilic persons during erotic picture viewing, the condition of erotic picture viewing was contrasted with non-erotic emotional picture viewing. This was done to ensure that both stimuli categories, i.e. erotic and non-erotic emotional picture viewing, were as closely comparable as possible and only differ in one dimension, which was the erotic dimension. The emotional component of the pictures was controlled for by using non-erotic pictures, which also induced emotions. Hence, contrasting these two stimuli categories enables a specific focus on the neural processing of erotic, i.e. sexual pictures.

It was shown that erotic picture viewing led to increased activation compared to non-erotic emotional picture viewing. In addition, neural activity was increased in healthy when compared to patients with pedophilia. The results showed that the patient group had reduced neuronal activations in subcortical regions, especially the hypothalamus, dorsal midbrain, as well as in cortical regions like the dorsolateral prefrontal cortex, when they viewed erotic pictures of adults, as opposed to pictures of children.

Interestingly, reduced neuronal activations in the pedophilia group were also observed during non-erotic emotional picture viewing. Participants with pedophilia showed decreased neuronal activity, especially in the dorsomedial prefrontal cortex, the retrosplenial cortex, and the left amygdala–hippocampal region.

In a last step it was explored as to whether the behavioural scores of the MSI can be related to neural activity in certain brain areas that were abnormally involved in non-erotic emotional and erotic processing. Neural activity in the dorsolateral prefrontal cortex during erotic picture viewing, when compared to non-erotic emotional picture viewing, was indeed correlated with MSI scores. More specifically,

there was a significant negative correlation between the MSI subscale for the sexual abuse of children and signal intensities in this region. This means, the higher the score for sexual abuse of children, the lower the signals obtained during erotic picture viewing (when compared to non-erotic emotional picture viewing) in the dorsolateral prefrontal cortex. Since subcortical regions involved in vegetative-autonomic processes in response to sexual stimuli, i.e. changes in heart rate or skin conductance, are influenced by cortical regions like the dorsolateral prefrontal cortex [56], this pattern might indicate an abnormal cortical mechanism of sexual processing in pedophilia.

The results of this particular imaging study showed abnormal neural activity in subcortical and cortical brain regions in pedophilic patients during visual processing of erotic stimuli. Subcortical regions like the hypothalamus and the dorsal midbrain are involved in the vegetative-autonomic component of sexual arousal in healthy subjects, such as changes in heart rate, respiration, or skin conductance [21, 28, 57]. The findings suggest that recruitment of vegetative-autonomic regions during viewing of sexually arousing stimuli of adults is impaired in persons with pedophilia. This might account for their lack of sexual interest towards adults, which needs to be further explored in future studies. Although the altered neural activations in the dorsomedial prefrontal cortex of individuals with pedophilia were related specifically to non-erotic emotional processing in the present study, the neural activity of prefrontal regions might serve as target region for therapeutic approaches (please see details below).

Perspectives: Neurofeedback in Paraphilia Using Real-Time fMRI

Regions which show abnormal neural activity in paraphilic patients, specifically persons with pedophilia, include subcortical regions like the amygdala [38•, 50••] and medial prefrontal areas such as the aforementioned dorsomedial prefrontal cortex [45] or the anterior cingulate cortex [42••, 44, 58].

The pattern of frontal brain changes can also be confirmed by a recent meta-analysis by Fonteille et al. [37••]. They showed that brain lesions related to pedophilia mainly occur in frontal and temporal regions. Moreover, again on the level of fMRI, studies have shown a comparable pattern of neural activity in pedophilic patients and healthy participants, if both groups are presented with pictures according to their sexual greatest sexual interest [37••, 42••]. Neural activity is similar between individuals with pedophilia when being presented with pictures of prepubescent nude girls or boys and neurotypical participants when being presented with pictures of adult nude women or men. More specifically, Poeppl et al. [42••] showed hyperactivity in medial prefrontal regions occurred in persons with pedophilia when viewing pictures of nude children [42••].

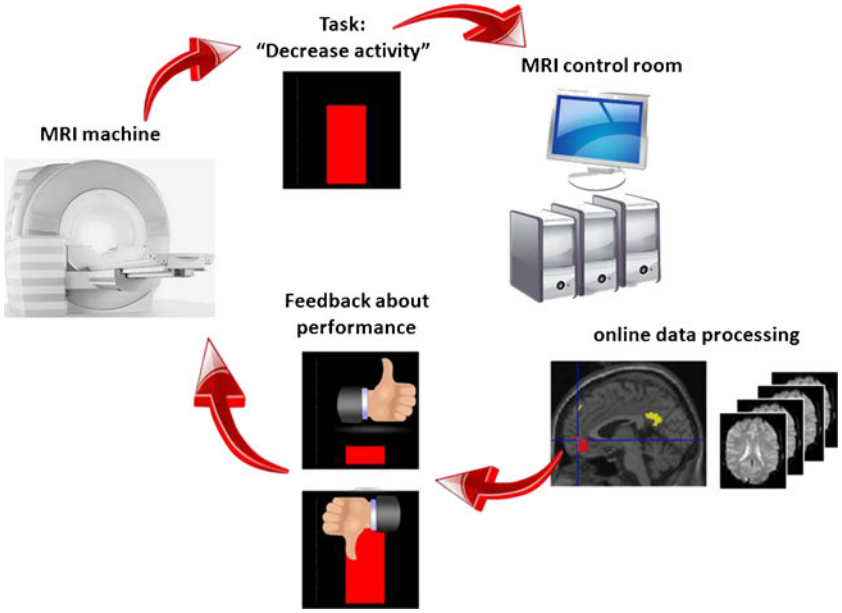

Fig. 1 Neurofeedback using rtfMRI. Image prepared by CW. While being in an MRI machine, participants are presented with simple pictures of their own brain activity. A sensitive region for this can be determined beforehand by a specifically designed task [63] (e.g., passive viewing of standardized sexual pictures, as in [45]). Participants can be instructed to decrease their neural activity by using certain cognitive strategies. The neural changes are immediately processed by high-performance computers. The participant will receive a feedback. In case of a negative feedback, the cognitive strategy needs to be optimized. In case of a positive feedback, the participants can contain and improve the cognitive strategy, which led to a decreased activity in the region on interest. Combining principles of cognitive-behavioural therapy with physical brain stimulation, this technique bears new therapeutic approaches in treatment of psychiatric disorders

These patterns of neural activation in medial prefrontal regions during sexual arousal can serve for the development of automatic classification algorithms between paraphilic and non-paraphilic groups [43••] and can also be targeted in imaging studies using neurofeedback. This new imaging technique is a promising tool for treatment of psychiatric disorders in general as well as sexual deviance/pedophilia [59••].

Since increased neural activity in prefrontal brain areas was shown in persons with pedophilia while being presented with pictures of nude children [37••, 42••], it may be possible - as explained in more detail below - for pedophilic patients to develop cognitive strategies to control and decrease neural activity of prefrontal brain regions while being presented with arousing pictures.

In order to focus on therapy approaches, self-management skills on the behavioural level can be applied. As such, the Berlin Prevention Project Dunkelfeld (PPD) [13] addressed self-identified persons with pedophilia, who are motivated to change their sexual behaviour, to seek professional help and to participate in this research and treatment project [13]. In line with this concept to provide self-management skills, also fMRI-based neurofeedback can be applied to further improve cognitive strategies to control deviant sexual thoughts and potentially avoid committing child sexual abuse. While in an MRI machine, participants are continuously updated about their neural activity in a certain brain region, such as the amygdala or the medial prefrontal cortex.

This is done by showing to the participant changing neural activity of this particular region on a screen. Changes of neural activity are converted in an easy to understand picture, such as growing or shrinking bars as illustrated in Fig. 1. This continuously changing picture is projected on a screen that the participant can see through a mirror mounted on the headcoil, as is usual in fMRI experiments. Since this neurofeedback about the participant's own neural activity is made in real time, the technique has been described as real-time fMRI (rtfMRI).

Studies using rtfMRI have shown that self-regulation of neural activity in the amygdala [60] or medial prefrontal regions [61] is possible. Participants were able to up- or down-regulate neural activity in this region by using cognitive strategies. Interestingly, a recent study by Linden [62••] showed that neurofeedback in a group of depressed patients leads to faster improvement of depression severity and hence more effective treatment than compared to a depressed group that practiced the same cognitive strategies but without neurofeedback. The results suggest that acquired skills to voluntarily influence activity of the central nervous system in general were more effective than gaining control of physiological functions of the peripheral nervous system, such as the ability to influence the heart rate via ECG biofeedback (electrocardiogram). Since the activity of the brain is central for integrating and coordinating processes of the peripheral nervous system and generating behaviour, influencing physiological processes at its core results in robust effects. Neurofeedback through rtfMRI has several important advantages as it combines the principles of cognitive-behavioural therapy with physical brain stimulation such as transcranial magnetic stimulation (TMS). Persons with pedophilia, which have learned through rtfMRI to decrease neural activity in medial prefrontal brain regions while viewing sexual arousing stimuli, might be able to use these cognitive strategies in everyday life. This can be seen as a tool to lower distress due to sexual interest in children and/or prevent criminal sexual acts.

Neurofeedback might lead to more stable long-term effects in the treatment of sexual deviances and other mental disorders, which has to be proven in future studies. However, this approach is seen as having great potential to be a possible first therapeutic application of functional imaging in the area of mental health research in general and in the area for treating paraphilia/pedophilia specifically [59••].

Conclusions

Paraphilia, specifically pedophilia, is a complex disorder, which affects individuals on the emotional, sexual, motivational, and vegetative level. The first line of research using functional magnetic resonance imaging in combination with emotional and/ or sexual stimuli showed that pedophilia is likely associated with altered brain activity particularly in the frontal brain areas and the temporal lobe. Evolving neuroimaging technology makes it possible to investigate neural underpinnings of psychiatric disorders. Moreover, neurofeedback through real-time fMRI bears the potential to establish treatment effects on the neural level and/or to support evaluation of risks to (re)offend.

Conflict of Interest Christine Wiebking declares that she has no conflict of interest.

Georg Northoff declares that he has no conflict of interest.

References

Papers of particular interest, published recently, have been highlighted as:

- • Of importance
- •• Of major importance

1. Diagnostic and statistical manual of mental disorders, text revision (DSM-IV-TR), 4th edn. Washington, DC: American Psychiatric Association: APA; 2000.
2. Fagan PJ, Wise TN, Schmidt Jr. CW, Berlin FS. Pedophilia. JAMA [Internet]. 2002/11/19 ed. 2002;288(19):2458–65. Available from: http://www.ncbi.nlm.nih.gov/entrez/query.fcgi?cmd=Retrieve&db=PubMed&dopt=Citation&list_uids=12435259.

3. •• Seto MC. Pedophilia. Annu Rev Clin Psychol [Internet]. 2009/03/31 ed. 2009;5:391–407. Available from: http://www.ncbi.nlm.nih.gov/entrez/query.fcgi?cmd=Retrieve&db=PubMed&dopt=Citation&list_uids=19327034. *This article provides a comprehensive review of pedophilia. It focuses on the diagnosis, assessment, and intervention for pedophilia*.
4. Seto MC, Lalumiere ML. A brief screening scale to identify pedophilic interests among child molesters. Sex Abuse. 2001;13(1):15–25.
5. Blanchard R, Klassen P, Dickey R, et al. Sensitivity and specificity of the phallometric test for pedophilia in nonadmitting sex offenders. Psychol Assess [Internet]. 2001/04/03 ed. 2001;13(1):118–26. Available from: http://www.ncbi.nlm.nih.gov/pubmed/11281033.
6. Maletzky BM, Steinhauser C. A 25-year follow-up of cognitive/behavioral therapy with 7,275 sexual offenders. Behav Modif [Internet]. 2002/04/19 ed. 2002;26(2):123–47. Available from: http://www.ncbi.nlm.nih.gov/pubmed/11961909.
7. Seto MC, Murphy WD, Page J, Ennis L. Detecting anomalous sexual interests in juvenile sex offenders. Ann N Y Acad Sci [Internet]. 2003/07/04 ed. 2003;989:118–53. Available from: http://www.ncbi.nlm.nih.gov/entrez/query.fcgi?cmd=Retrieve&db=PubMed&dopt=Citation&list_uids=12839891.
8. O'Donohue W. A critique of the proposed DSM-V diagnosis of pedophilia. Arch Sex Behav. 2010;39(3):587–90.
9. American Psychiatric Association. American Psychiatric Association (APA). Diagnostic and statistical manual of mental disorders. 4th edn. Washington, DC; 2000.
10. Hanson RK, Morton-Bourgon KE. The accuracy of recidivism risk assessments for sexual offenders: a meta-analysis of 118 prediction studies. Psychol Assess [Internet]. 2009 Mar [cited 2012 Nov 1];21(1):1–21. Available from: http://www.ncbi.nlm.nih.gov/pubmed/19290762.
11. Sedlak AJ, Broadhurst DD. Executive summary of the third National Incidence Study of Child Abuse and Neglect (NIS-3). National Center on Child Abuse and Neglect (DHHS), Washington, DC.; 1996.
12. Murray JB. Psychological profile of pedophiles and child molesters. J Psychol [Internet]. 2000/04/15 ed. 2000;134(2):211–24. Available from: http://www.ncbi.nlm.nih.gov/entrez/query.fcgi?cmd=Retrieve&db=PubMed&dopt=Citation&list_uids=10766112.
13. Beier KM, Neutze J, Mundt I a, et al. Encouraging self-identified pedophiles and hebephiles to seek professional help: first results of the Prevention Project Dunkelfeld (PPD). Child Abuse Neglect [Internet]. 2009 Aug [cited 2012 Nov 27];33(8):545–9. Available from: http://www.ncbi.nlm.nih.gov/pubmed/19765825.
14. Huettel SA, Song AW, McCarthy G. Functional magnetic resonance imaging. 2nd ed. Sunderland: Sinauer Associates, Inc; 2008. p. 510.
15. Ogawa S, Tank DW, Menon R, et al. Intrinsic signal changes accompanying sensory stimulation: functional brain mapping with magnetic resonance imaging. Proc Natl Acad Sci USA [Internet]. 1992 Jul 1 [cited 2012 Oct 24];89(13):5951–5. Available from: http://www.pubmedcentral.nih.gov/articlerender.fcgi?artid=402116&tool=pmcentrez&rendertype=abstract.
16. Mansfield P. Multi-planar image formation using NMR spin echoes. J Phys C Solid State Phys. 1977;10:L55–8.
17. Feinberg D a, Yacoub E. The rapid development of high speed, resolution and precision in fMRI. NeuroImage [Internet]. Elsevier Inc.; 2012 Aug 15 [cited 2012 Nov 21];62(2):720–5. Available from: http://www.ncbi.nlm.nih.gov/pubmed/22281677.
18. Logothetis NK, Pauls J, Augath M, et al. Neurophysiological investigation of the basis of the fMRI signal. Nature [Internet]. 2001 Jul 12 [cited 2012 Nov 1];412(6843):150–7. Available from: http://www.ncbi.nlm.nih.gov/pubmed/11449264.
19. Lutti A, Thomas DL, Hutton C, Weiskopf N. High-resolution functional MRI at 3 T: 3D/2D echo-planar imaging with optimized physiological noise correction. Magn Reson Med: Official J Soc Magn Reson Med/ Soc Magn Reson Med [Internet]. 2012 Jul 20 [cited 2012 Nov 1]; Available from: http://www.ncbi.nlm.nih.gov/pubmed/22821858.
20. Redoute J, Stoleru S, Gregoire MC, et al. Brain processing of visual sexual stimuli in human males. Hum Brain Mapp [Internet]. 2000/12/01 ed. 2000;11(3):162–77. Available from: http://www.ncbi.nlm.nih.gov/entrez/query.fcgi?cmd=Retrieve&db=PubMed&dopt=Citation&list_uids=11098795.
21. Ferretti A, Caulo M, Del Gratta C, et al. Dynamics of male sexual arousal: distinct components of brain activation revealed by fMRI. Neuroimage [Internet]. 2005/06/18 ed. 2005;26(4):1086–96. Available from: http://www.ncbi.nlm.nih.gov/entrez/query.fcgi?cmd=Retrieve&db=PubMed&dopt=Citation&list_uids=15961048.
22. Mouras H, Stoleru S, Bittoun J, et al. Brain processing of visual sexual stimuli in healthy men: a functional magnetic resonance imaging study. Neuroimage [Internet]. 2003/10/22 ed. 2003;20(2):855–69. Available from: http://www.ncbi.nlm.nih.gov/entrez/query.fcgi?cmd=Retrieve&db=PubMed&dopt=Citation&list_uids=14568457.
23. Canli T, Gabrieli JD. Imaging gender differences in sexual arousal. Nat Neurosci [Internet]. 2004/03/30 ed. 2004;7(4):325–6. Available from: http://www.ncbi.nlm.nih.gov/entrez/query.fcgi?cmd=Retrieve&db=PubMed&dopt=Citation&list_uids=15048119.
24. Northoff G, Richter A, Gessner M, et al. Functional dissociation between medial and lateral prefrontal cortical spatiotemporal activation in negative and positive emotions: a combined fMRI/MEG study. Cereb Cortex [Internet]. 2000/01/20 ed. 2000;10(1):93–107. Available from: http://www.ncbi.nlm.nih.gov/entrez/query.fcgi?cmd=Retrieve&db=PubMed&dopt=Citation&list_uids=10639399.
25. Northoff G, Heinzel A, Bermpohl F, et al. Reciprocal modulation and attenuation in the prefrontal cortex: an fMRI study on emotional-cognitive interaction. Hum Brain Mapp [Internet]. 2004/02/03 ed. 2004;21(3):202–12. Available from: http://www.ncbi.nlm.nih.gov/entrez/query.fcgi?cmd=Retrieve&db=PubMed&dopt=Citation&list_uids=14755839.
26. Phan KL, Wager T, Taylor SF, Liberzon I. Functional neuroanatomy of emotion: a meta-analysis of emotion activation studies in PET and fMRI. Neuroimage [Internet]. 2002/05/29 ed. 2002;16(2):331–48. Available from: http://www.ncbi.nlm.nih.gov/entrez/query.fcgi?cmd=Retrieve&db=PubMed&dopt=Citation&list_uids=12030820.
27. Wiebking C, De Greck M, Duncan NW, et al. Are emotions associated with activity during rest or interoception? An exploratory fMRI study in healthy subjects. Neurosci Lett. 2011;491(1):87–92.
28. Karama S, Lecours AR, Leroux JM, et al. Areas of brain activation in males and females during viewing of erotic film excerpts. Hum Brain Mapp [Internet]. 2002/03/01 ed. 2002;16(1):1–13. Available from: http://www.ncbi.nlm.nih.gov/entrez/query.fcgi?cmd=Retrieve&db=PubMed&dopt=Citation&list_uids=11870922.
29. Hamann S, Herman RA, Nolan CL, Wallen K. Men and women differ in amygdala response to visual sexual stimuli. Nat Neurosci [Internet]. 2004/03/09 ed. 2004;7(4):411–6. Available from: http://www.ncbi.nlm.nih.gov/entrez/query.fcgi?cmd=Retrieve&db=PubMed&dopt=Citation&list_uids=15004563.
30. Cohen LJ, Galynker II. Clinical features of pedophilia and implications for treatment. J Psychiatr Pract [Internet]. 2005/06/30 ed. 2002;8(5):276–89. Available from: http://www.ncbi.nlm.nih.gov/entrez/query.fcgi?cmd=Retrieve&db=PubMed&dopt=Citation&list_uids=15985890.
31. Raymond NC, Coleman E, Ohlerking F, et al. Psychiatric comorbidity in pedophilic sex offenders. Am J Psychiatry [Internet]. 1999/05/18 ed. 1999;156(5):786–8. Available from: http://www.ncbi.nlm.nih.gov/entrez/query.fcgi?cmd=Retrieve&db=PubMed&dopt=Citation&list_uids=10327918.
32. Hall RCW, Hall RCW. A profile of pedophilia: definition, characteristics of offenders, recidivism, treatment outcomes, and forensic issues. Mayo Clinic proceedings. Mayo Clinic [Internet]. 2007

Apr;82(4):457–71. Available from: http://www.ncbi.nlm.nih.gov/pubmed/17418075.
33. Cohen LJ, Nikiforov K, Gans S, et al. Heterosexual male perpetrators of childhood sexual abuse: a preliminary neuropsychiatric model. Psychiatr Q [Internet]. 2002/11/07 ed. 2002;73(4):313–36. Available from: http://www.ncbi.nlm.nih.gov/entrez/query.fcgi?cmd=Retrieve&db=PubMed&dopt=Citation&list_uids=12418359.
34. Fagan PJ, Wise TN, Schmidt Jr. CW, Berlin FS. Pedophilia. JAMA [Internet]. 2002/11/19 ed. 2002;288(19):2458–65. Available from: http://www.ncbi.nlm.nih.gov/pubmed/12435259.
35. Cohen LJ, McGeoch PG, Watras-Gans S, et al. Personality impairment in male pedophiles. J Clin Psychiatry [Internet]. 2002/11/06 ed. 2002;63(10):912–9. Available from: http://www.ncbi.nlm.nih.gov/entrez/query.fcgi?cmd=Retrieve&db=PubMed&dopt=Citation&list_uids=12416601.
36. Burns JM, Swerdlow RH. Right orbitofrontal tumor with pedophilia symptom and constructional apraxia sign. Arch Neurol [Internet]. 2003/03/14 ed. 2003;60(3):437–40. Available from: http://www.ncbi.nlm.nih.gov/entrez/query.fcgi?cmd=Retrieve&db=PubMed&dopt=Citation&list_uids=12633158.
37. •• Fonteille V, Cazala F, Moulier V, Stoléru S. [Pedophilia: Contribution of neurology and neuroimaging techniques]. L'Encéphale [Internet]. 2012 Dec [cited 2012 Dec 28];38(6):496–503. Available from: http://www.ncbi.nlm.nih.gov/pubmed/23200616. *This review paper, currently only available in French language, reviews structural and functional neuroimaging studies of pedophilia. They find inconsistent results across studies and suggest confirmatory studies in combination with objective measures such as phallometry.*
38. • Harenski CL, Thornton DM, Harenski KA, et al. Increased Frontotemporal Activation During Pain Observation in Sexual Sadism. 2012;69(3):283–92. *This fMRI study compared sadistic and nonsadistic sexual offenders and found greater amygdala activation in sadists compared to nonsadists when viewing pain pictures. The results suggest context-dependent activity of brain regions that differs across groups*.
39. Mendez M, Shapira JS. Pedophilic behavior from brain disease. J Sex Med [Internet]. 2011 Apr [cited 2013 Jan 16];8(4):1092–100. Available from: http://www.ncbi.nlm.nih.gov/pubmed/21235721.
40. Dressing H, Obergriesser T, Tost H, et al. [Homosexual pedophilia and functional networks - an fMRI case report and literature review]. Fortschr Neurol Psychiatr [Internet]. 2001/11/13 ed. 2001;69(11):539–44. Available from: http://www.ncbi.nlm.nih.gov/entrez/query.fcgi?cmd=Retrieve&db=PubMed&dopt=Citation&list_uids=11704902.
41. Mendez MF, Chow T, Ringman J, et al. Pedophilia and temporal lobe disturbances. J Neuropsychiatr Clin Neurosci [Internet]. 2000/03/04 ed. 2000;12(1):71–6. Available from: http://www.ncbi.nlm.nih.gov/entrez/query.fcgi?cmd=Retrieve&db=PubMed&dopt=Citation&list_uids=10678516.
42. •• Poeppl TB, Nitschke J, Dombert B, et al. Functional cortical and subcortical abnormalities in pedophilia: a combined study using a choice reaction time task and fMRI. J Sex Med [Internet]. 2011 Jun 7 [cited 2012 Dec 30];8(6):1660–74. Available from: doi:10.1111/j.1743-6109.2011.02248.x. *This fMRI study compared individuals with pedophilia to non-pedophilic individuals while viewing pictures of nude prepubescents, pubescents, and adults. When viewing pictures of greatest sexual interest, brain activity was comparable between persons with pedophilia and non-pedophilic males*.
43. •• Ponseti J, Granert O, Jansen O, et al. Assessment of pedophilia using hemodynamic brain response to sexual stimuli. Arch Gen Psychiatry. 2012;69(2):187–94. *Basing on fMRI results of persons with pedophilia and non-pedophilic individuals, an automatic classification procedure of neural response patterns was used to distinguish both groups from each other. This method might be a promising objective tool to clinically diagnose pedophilia*.
44. Schiltz K, Witzel J, Northoff G, et al. Brain pathology in pedophilic offenders: evidence of volume reduction in the right amygdala and related diencephalic structures. Arch Gen Psychiatry [Internet]. 2007/06/06 ed. 2007;64(6):737–46. Available from: http://www.ncbi.nlm.nih.gov/entrez/query.fcgi?cmd=Retrieve&db=PubMed&dopt=Citation&list_uids=17548755.
45. Walter M, Witzel J, Wiebking C, et al. Pedophilia is linked to reduced activation in hypothalamus and lateral prefrontal cortex during visual erotic stimulation. Biol Psychiatry [Internet]. 2007/04/03 ed. 2007;62(6):698–701. Available from: http://www.ncbi.nlm.nih.gov/entrez/query.fcgi?cmd=Retrieve&db=PubMed&dopt=Citation&list_uids=17400196.
46. Cohen LJ, Gans SW, McGeoch PG, et al. Impulsive personality traits in male pedophiles versus healthy controls: is pedophilia an impulsive-aggressive disorder? Compr Psychiatry [Internet]. 2002/03/15 ed. 2002;43(2):127–34. Available from: http://www.ncbi.nlm.nih.gov/entrez/query.fcgi?cmd=Retrieve&db=PubMed&dopt=Citation&list_uids=11893991.
47. Marshall WL, Hamilton K, Fernandez Y. Empathy deficits and cognitive distortions in child molesters. Sex Abuse [Internet]. 2001/04/11 ed. 2001;13(2):123–30. Available from: http://www.ncbi.nlm.nih.gov/pubmed/11294123.
48. Cantor JM, Kabani N, Christensen BK, et al. Cerebral white matter deficiencies in pedophilic men. J Psychiatr Res [Internet]. 2008 Feb [cited 2012 Dec 25];42(3):167–83. Available from: http://www.ncbi.nlm.nih.gov/pubmed/18039544.
49. Cantor JM, Blanchard R. White matter volumes in pedophiles, hebephiles, and teleiophiles. Arch Sex Behav [Internet]. 2012 Aug [cited 2012 Nov 27];41(4):749–52. Available from: http://www.ncbi.nlm.nih.gov/pubmed/22476520.
50. •• Sartorius A, Ruf M, Kief C, et al. Abnormal amygdala activation profile in pedophilia. Eur Arch Psychiatry Clin Neurosci [Internet]. 2008/05/28 ed. 2008;258(5):271–7. Available from: http://www.ncbi.nlm.nih.gov/entrez/query.fcgi?cmd=Retrieve&db=PubMed&dopt=Citation&list_uids=18504635. *This fMRI study compares persons with pedophilia to non-pedophilic individulas while exposed to images of men, women, boys or girls. They found significantly higher amygdala activation in persons with pedophilia while viewing pictures of boys compared to non-pedophilic persons. They suggest that a mechanism present in healthy controls that reduces emotional salience of children may be impaired in individuals with pedophilia*.
51. Schiffer B, Peschel T, Paul T, et al. Structural brain abnormalities in the frontostriatal system and cerebellum in pedophilia. J Psychiatr Res [Internet]. 2006/08/01 ed. 2007;41(9):753–62. Available from: http://www.ncbi.nlm.nih.gov/entrez/query.fcgi?cmd=Retrieve&db=PubMed&dopt=Citation&list_uids=16876824.
52. Nichols HR, Molinder I. Multiphasic sex inventory. Washington: Nichols & Molinder Assessments; 1984.
53. Lang PJ, Bradley MM, Cuthbert BN. International Affective Picture System (IAPS). Gainesville, Florida: NIMH Center for the Study of Emotion and Attention; 1997.
54. Lang PJ, Bradley MM, Cuthbert BN. International affective picture system (IAPS): affective ratings of pictures and instruction manual. Florida, Gainesville: NIMH, Center for the Study of Emotion & Attention; 2005.
55. Mikels JA, Fredrickson BL, Larkin GR, et al. Emotional category data on images from the international affective picture system. Behav Res Meth [Internet]. 2005 Nov [cited 2012 Dec 29];37(4):626–30. Available from: http://www.pubmedcentral.nih.gov/articlerender.fcgi?artid=1808555&tool=pmcentrez&rendertype=abstract.
56. Beauregard M, Levesque J, Bourgouin P. Neural correlates of conscious self-regulation of emotion. J Neurosci. 2001;21.
57. Bancroft J. The endocrinology of sexual arousal. J Endocrinol. 2005;186:411–27.

58. Schiffer B, Paul T, Gizewski E, et al. Functional brain correlates of heterosexual paedophilia. Neuroimage [Internet]. 2008/03/25 ed. 2008;41(1):80–91. Available from: http://www.ncbi.nlm.nih.gov/entrez/query.fcgi?cmd=Retrieve&db=PubMed&dopt=Citation&list_uids=18358744.
59. •• Renaud P, Joyal C, Stoleru S, et al. Real-time functional magnetic imaging—brain–computer interface and virtual reality: promising tools for the treatment of pedophilia. Prog Brain Res. 2012;192. *This article speaks about real-time fMRI as treatment for pedophilia. Virtual characters depicting sexual stimuli relevant to pedophilia are proposed to be a useful tool*.
60. Zotev V, Krueger F, Phillips R, et al. Self-regulation of amygdala activation using real-time FMRI neurofeedback. PLos One [Internet]. 2011 Jan [cited 2012 Nov 2];6(9):e24522. Available from: http://www.pubmedcentral.nih.gov/articlerender.fcgi?artid=3169601&tool=pmcentrez&rendertype=abstract.
61. Li X, Hartwell KJ, Borckardt J, et al. Volitional reduction of anterior cingulate cortex activity produces decreased cue craving in smoking cessation: a preliminary real-time fMRI study. Addiction Biol [Internet]. 2012 Mar 28 [cited 2012 Nov 11]; Available from: http://www.ncbi.nlm.nih.gov/pubmed/22458676.
62. •• Linden DEJ, Habes I, Johnston SJ, et al. Real-time self-regulation of emotion networks in patients with depression. PLos One [Internet]. 2012 Jan [cited 2012 Oct 30];7(6):e38115. Available from: http://www.pubmedcentral.nih.gov/articlerender.fcgi?artid=3366978&tool=pmcentrez&rendertype=abstract. *A proof-of-concept study showing that patients with depression learned to upregulate brain areas involved in the generation of positive emotions using neurofeedback. Their clinical symptoms improved significantly, whilst a control group that underwent training with the same cognitive strategies but without neurofeedback did not improve clinically.*
63. Weiskopf N, Sitaram R, Josephs O, et al. Real-time functional magnetic resonance imaging: methods and applications. Magn Reson Imag [Internet]. 2007 Jul [cited 2012 Nov 15];25(6):989–1003. Available from: http://www.ncbi.nlm.nih.gov/pubmed/17451904